

# Nursing HESI-Exit

## HESI Exit Certification Exam

Questions And Answers PDF Format:

For More Information – Visit link below:  
<https://www.certsgrade.com/>

*Version* = Product



# Latest Version: 6.0

## Question: 1

The nurse reviews the collected data and recognizes that follow-up is immediately required on which aspects of the patient's condition? (Select all that apply)

- A. Medical history
- B. Surgical history
- C. Abdominal assessment
- D. Reports of nausea and vomiting
- E. Vital signs
- F. Bowel and bladder reports
- G. Laboratory results

**Answer: B, C, D, F, G**

Explanation:

The client is showing some of the primary signs of a small bowel obstruction (i.e., abdominal pain and distension, vomiting, and possible constipation). The client also has a history of recent abdominal surgery—one of the most significant risk factors of small bowel obstruction. The client's laboratory results indicate possible inflammation consistent with small bowel obstruction (i.e., elevated WBC count) as well as possible dehydration (i.e., elevated creatinine and BUN values). Amber-colored urine could also indicate dehydration. It is essential for the nurse to alert the client's primary care provider about these findings as soon as possible. The patient's medical history is not concerning for any disease process related to the client's current symptoms, especially because urinary retention has been ruled out with the completion of the bladder scan and finding a post void residual measurement that is within normal limits. The patient's vital signs are stable at this point. Although the client's heart rate and respiration rate are slightly elevated, that is to be expected in the setting of acute pain.

## Question: 2

Based on the notes, laboratory values, and vital signs, the nurse understands that the client is most likely experiencing \_\_\_\_\_.

- A. cholecystitis
- B. nephrolithiasis
- C. a small bowel obstruction

**Answer: C**

Explanation:

The client is showing some of the primary signs of small bowel obstruction, including colicky abdominal pain and distension, vomiting, and constipation. Hyperactive bowel sounds, elevated WBCs, and signs of

dehydration (i.e., elevated creatinine, elevated BUN) are also consistent with small bowel obstruction. Although cholecystitis (i.e., inflammation of the gallbladder) can present as abdominal pain in the right upper quadrant, the pain often radiates to the back or shoulders and is usually accompanied by an increase in bloating or gas, rather than no flatus. Cholecystitis is also often associated with an elevation in AST and ALT indicating liver damage. These laboratory values are within the normal range for this client. Although nephrolithiasis (i.e., kidney stones) could also cause acute pain and nausea/vomiting, the pain is typically located in the flank area and is often described as sharp or shooting and is not associated with distension.

### Question: 3

The nurse on the medical-surgical unit reviews the collected data.

a. The nurse is monitoring the client closely for complications and recognizes that the client is at the most immediate risk for and \_\_\_\_\_. (Select two answers.)

- A. urinary retention
- B. infection
- C. dehydration
- D. respiratory distress

**Answer: B, C**

Explanation:

The client is at risk for infection due to the possibility of the bowel obstruction leading to a bowel perforation and subsequent peritonitis. The client is also directly at risk for dehydration because the small intestine is unable to properly absorb fluids due to the obstruction and due to the nothing-by-mouth (NPO) status needed to rest the bowel. Although the client is not at direct risk for urinary retention his urine output should be monitored closely as an indication of hydration status and due to the client's medical history of benign prostatic hypertrophy. The client is also not at direct risk for respiratory distress as a result of the small bowel obstruction, and the client's respirations will likely normalize once his pain is under control.

### Question: 4

HOTSPOT

The nurse anticipates receiving orders from the primary care provider. For each potential order, specify whether each potential order is indicated or not indicated for the client's condition by marking in the corresponding column.

Potential Orders	Indicated	Not Indicated
Initiate a clear liquid diet.	<input type="radio"/>	<input type="radio"/>
Insert a nasogastric tube, and set it to low intermittent suction.	<input type="radio"/>	<input type="radio"/>
Start a normal saline (0.9% NaCl) IV at 125 mL/hr.	<input type="radio"/>	<input type="radio"/>
Administer morphine sulfate 5 mg IV every 4 hours as needed for pain.	<input type="radio"/>	<input type="radio"/>
Insert a rectal tube.	<input type="radio"/>	<input type="radio"/>
Administer metoclopramide 10 mg IV three times daily for constipation.	<input type="radio"/>	<input type="radio"/>

**Answer:**

Potential Orders	Indicated	Not Indicated
Initiate a clear liquid diet.	<input type="radio"/>	<input checked="" type="radio"/>
Insert a nasogastric tube, and set it to low intermittent suction.	<input checked="" type="radio"/>	<input type="radio"/>
Start a normal saline (0.9% NaCl) IV at 125 mL/hr.	<input checked="" type="radio"/>	<input type="radio"/>
Administer morphine sulfate 5 mg IV every 4 hours as needed for pain.	<input checked="" type="radio"/>	<input type="radio"/>
Insert a rectal tube.	<input type="radio"/>	<input checked="" type="radio"/>
Administer metoclopramide 10 mg IV three times daily for constipation.	<input type="radio"/>	<input checked="" type="radio"/>

Explanation:

With a bowel obstruction, bowel rest is indicated, and the patient would be placed on strict NPO status, rather than on a clear liquid diet. A nasogastric tube set to suction is indicated because this aids in bowel decompression and promotes comfort by removing the stomach contents and reducing emesis. Fluid replacement via normal saline IV is indicated because this patient is at risk for dehydration due to his NPO status and due to the bowel being unable to optimally absorb fluids due to the obstruction. Pain management, such as with IV morphine, is a nursing priority because the client may be in acute pain with the obstruction. A rectal tube would not be helpful in the case of small bowel obstruction. Metoclopramide, although it is a treatment for constipation, is directly contraindicated in bowel obstructions because it induces peristalsis of the intestines.

## Question: 5

The nurse is preparing to insert the nasogastric tube. Of the following options, which two actions should the nurse take? (Select 2 answers)

A. Determine the appropriate insertion length of the nasogastric tube by measuring from the tip of the client's chin to his earlobe and from his earlobe to his xiphoid process.

- B. Instruct the client to swallow and place his chin to his chest while inserting the tube through the client's left nostril and down his pharynx.
- C. Once the nasogastric tube is inserted, use bedside ultrasound to confirm that the tube is located in the correct position in the stomach.
- D. Following insertion of the nasogastric tube, have the client lie flat in bed to aid with gastric decompression.
- E. Provide water-soluble lubricant to the client. or assist in administering it to his lips or inside his nares in case of dryness or irritation.

**Answer: B, E**

Explanation:

Giving the client instructions to tilt his chin and swallow during the insertion process helps guide the nasogastric tube into his stomach, rather than into his lungs. Providing proper oral care and skin care is a priority nursing intervention following nasogastric tube placement and NPO status because the client's mucous membranes are at risk for becoming dry and the nares are at risk for irritation from the nasogastric tube. The nurse should not measure from the tip of the chin to the earlobe to the xiphoid process in order to find the appropriate length but should instead measure from the tip of the nose to the earlobe to the xiphoid process. Ultrasound is not used to determine correct tube placement: instead, x-ray would be used if imaging were necessary. Finally, it is contraindicated to have the client lie flat following nasogastric tube insertion due to the risk of aspiration of his gastric contents. The client should instead be kept in a semi-Fowler's or upright position.

### Question: 6

Highlight the findings in the nurses' notes that are the most concerning indicators that the patient's condition is declining.

1700: Nasogastric tube is inserted. Client reports feeling comfortable there is no further emesis, and pain is currently 3/10 in the abdomen. Client reports toleration of his current pain level.

1830: Client voided 500 mL of clear amber urine. There was 250 mL of clear bile gastric output via suction.

2230: Client requested assistance with reaching the television remote; he was observed lying very still in bed and was unwilling to lean forward to reach for the remote due to the pain in his abdomen. Client reports that his pain is 9/10 on the right side of his abdomen. Client has hyperactive bowel sound\$ the abdomen is board-like upon palpation. The primary care physician was notified of these findings.

A. See explanation given below

**Answer: A**

Explanation:

1700: Nasogastric tube is inserted. Client reports feeling comfortable. There is no further emesis, and pain is currently 3/10 in the abdomen. Client reports toleration of his current pain level.

1830: Client voided 500 mL of clear amber urine. There was 250 mL of clear bile gastric output via suction.

2230: Client requested assistance with reaching the television remote; he was observed lying very still in bed and was unwilling to lean forward to reach for the remote due to the pain in his abdomen. Client reports that his pain is 9/10 on the right side of his abdomen. Client has hyperactive bowel sounds; the abdomen is board-like upon palpation. The primary care physician was notified of these findings.

The client is demonstrating signs of peritonitis, a very serious complication of small bowel obstruction that can result if the bowel perforates and the contents infect the abdominal cavity. Peritonitis should be suspected in patients demonstrating increased or severe abdominal pain, muscle guarding or unwillingness to move due to pain, and a board-like abdomen. The provider should be notified immediately because this development often requires emergency surgery. Although the patient's urine is amber in color and should continue to be monitored, this is not a change from when the patient was admitted and is not a sign of declining condition at this time.

### Question: 7

Which of the following findings require immediate follow-up? (Select all that apply)

- A. Heart rate
- B. Headache
- C. Fetal movement
- D. Maternal blood pressure
- E. Brisk reflexes
- F. Epigastric pain
- G. Respiratory rate

**Answer: C, D**

Explanation:

Fetal well-being should be assessed to ensure that adequate oxygenation and blood flow are being delivered through the placenta. The severely elevated blood pressure puts the client at risk for seizures and placental abruption and should be managed immediately. All other abnormal findings can be addressed after immediately initiating fetal monitoring and maternal blood pressure management measures.

### Question: 8

HOTSPOT

For the list of client findings below, specify for each whether it is consistent with the disease processes of placental abruption, preeclampsia, and maternal heart failure. Select all supported disease processes for each finding.

Client Findings	Placental Abruption	Preeclampsia	Maternal Heart Failure
Blood pressure	<input type="checkbox"/>	<input type="checkbox"/>	<input type="checkbox"/>
Headache	<input type="checkbox"/>	<input type="checkbox"/>	<input type="checkbox"/>
Lower extremity swelling	<input type="checkbox"/>	<input type="checkbox"/>	<input type="checkbox"/>
Epigastric pain	<input type="checkbox"/>	<input type="checkbox"/>	<input type="checkbox"/>
Temperature	<input type="checkbox"/>	<input type="checkbox"/>	<input type="checkbox"/>
Respiratory rate	<input type="checkbox"/>	<input type="checkbox"/>	<input type="checkbox"/>

**Answer:**

Client Findings	Placental Abruption	Preeclampsia	Maternal Heart Failure
Blood pressure	<input type="checkbox"/>	<input checked="" type="checkbox"/>	<input type="checkbox"/>
Headache	<input type="checkbox"/>	<input checked="" type="checkbox"/>	<input type="checkbox"/>
Lower extremity swelling	<input type="checkbox"/>	<input checked="" type="checkbox"/>	<input checked="" type="checkbox"/>
Epigastric pain	<input type="checkbox"/>	<input checked="" type="checkbox"/>	<input type="checkbox"/>
Temperature	<input checked="" type="checkbox"/>	<input checked="" type="checkbox"/>	<input checked="" type="checkbox"/>
Respiratory rate	<input checked="" type="checkbox"/>	<input type="checkbox"/>	<input checked="" type="checkbox"/>

Explanation:

Preeclampsia symptoms include elevated blood pressure, severe headache, epigastric pain, and overactive reflexes. Preeclampsia can affect multiple organs throughout the body secondary to decreased blood flow throughout the blood vessels to important organs. Placental abruption is an emergency in and of itself, but it can also be caused by preeclampsia. Signs of placental abruption can include severe abdominal pain, tachycardia, vaginal bleeding, and in worst cases absent fetal movement. Maternal heart failure presents with symptoms of chest pain, difficulty breathing, increased edema, and low oxygen saturation. For all three conditions, the client would present as normothermic.

## Question: 9

HOTSPOT

For the following list of potential nursing interventions, specify whether each one is indicated or not indicated for the care of the client while she is on the magnesium sulfate drip.

Potential Nursing Interventions	Indicated	Not Indicated
Assess headache every 2 hours.	<input type="radio"/>	<input type="radio"/>
Assess deep tendon reflexes every 2 hours.	<input type="radio"/>	<input type="radio"/>
Auscultate lung sounds every 1–2 hours.	<input type="radio"/>	<input type="radio"/>
Monitor blood pressure every hour.	<input type="radio"/>	<input type="radio"/>
Evaluate edema every 1–2 hours.	<input type="radio"/>	<input type="radio"/>
Monitor magnesium levels.	<input type="radio"/>	<input type="radio"/>
Strict input and output monitoring.	<input type="radio"/>	<input type="radio"/>

**Answer:**

Potential Nursing Interventions	Indicated	Not Indicated
Assess headache every 2 hours.	<input type="radio"/>	<input checked="" type="radio"/>
Assess deep tendon reflexes every 2 hours.	<input checked="" type="radio"/>	<input type="radio"/>
Auscultate lung sounds every 1–2 hours.	<input checked="" type="radio"/>	<input type="radio"/>
Monitor blood pressure every hour.	<input checked="" type="radio"/>	<input type="radio"/>
Evaluate edema every 1–2 hours.	<input type="radio"/>	<input checked="" type="radio"/>
Monitor magnesium levels.	<input checked="" type="radio"/>	<input type="radio"/>
Strict input and output monitoring.	<input checked="" type="radio"/>	<input type="radio"/>

Explanation:

The client's deep tendon reflexes should be monitored hourly to assess for magnesium toxicity. Auscultation lung sounds every 1–2 hours is necessary to ensure that the client does not develop fluid overload or

pulmonary edema. Monitoring blood pressure readings hourly is indicated to assure that the client's blood pressure is well controlled. Monitoring magnesium levels is indicated in order to maintain a therapeutic level. Strict input and output monitoring is indicated to further ensure that fluid overload is avoided.

### Question: 10

The nurse has reviewed the history and physical and the physician orders. According to the new orders, the nurse should first\_\_\_\_\_.

- A. start the magnesium sulfate drip
- B. inserts a Foley catheter
- C. administer an antacid
- D. draw blood for a baseline magnesium level

**Answer: A**









Explanation:

The nurse's first priority should be to initiate the magnesium infusion to prevent the progression of preeclampsia and the onset of seizure activity. Magnesium induces vasodilation of the blood vessels, including the cerebral vascular system, which helps decrease the risk of seizures. Magnesium is also a calcium antagonist, which causes a decrease in cerebral and vascular resistance. Additionally, magnesium provides neuroprotection for the fetus.

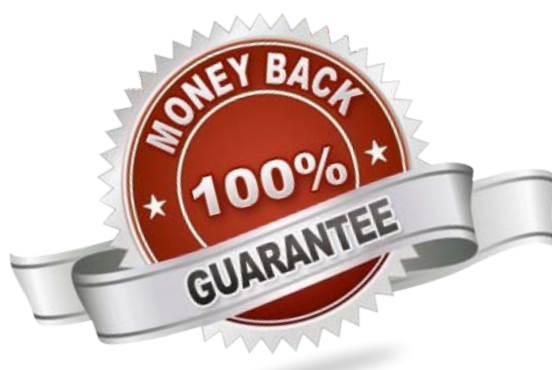


For More Information – **Visit link below:**  
<https://www.certsgrade.com/>

## PRODUCT FEATURES

-  **100% Money Back Guarantee**
-  **90 Days Free updates**
-  **Special Discounts on Bulk Orders**
-  **Guaranteed Success**
-  **50,000 Satisfied Customers**
-  **100% Secure Shopping**
-  **Privacy Policy**
-  **Refund Policy**

**16 USD Discount Coupon Code: NB4XKTMZ**



Visit us at: <https://www.certsgrade.com/pdf/hesi-exit>