

# Radiology CI

**ARRT Cardiac-Interventional Radiography (CI)**

**Questions And Answers PDF Format:**

**For More Information – Visit link below:**

**<https://www.certsgrade.com/>**

*Version* = Product



# Latest Version: 6.0

## Question: 1

Which of the following is MOST likely the normal range of glucose level in adult?

- A. 2.21-2.52 mEq/L (at pH 7.4 and 37°C).
- B. 2.3-4.3 mg/dL.
- C. 70-112 mg/dL.
- D. 2.2-7.3 mg/dL.

**Answer: C**

Explanation:

The question asks for the normal range of glucose level in an adult. To determine the correct answer, it is essential to understand typical laboratory values for various blood components, each measured in specific units relevant to their biological context.

Among the provided options: - 2.21-2.52 mEq/L is a measurement typically used for electrolytes like calcium, not glucose. This range, especially noted at a specific pH and temperature, indicates a value appropriate for calcium in the blood, thus unrelated to glucose levels. - 70-112 mg/dL is the standard measurement for blood glucose levels in adults. This range indicates a normal fasting blood sugar level, which is crucial for diagnosing and managing conditions such as diabetes and hypoglycemia. - 2.3-4.3 mg/dL represents a normal range for inorganic phosphorus in the blood, which is vital for bone health and energy storage but is not related to glucose. - 2.2-7.3 mg/dL is the range for uric acid levels, particularly in adult females. Uric acid is a breakdown product of purine nucleotides and is not a measure of glucose.

Therefore, the correct answer to the question about the normal glucose level in an adult is "70-112 mg/dL." This range reflects the typical blood glucose level necessary to maintain healthy metabolic function and is the standard reference range used in medical practice to assess whether a person's glucose level is within normal limits, potentially indicative of hyperglycemia (if above the range) or hypoglycemia (if below the range).

## Question: 2

In a platelet count, low results are referred to as:

- A. Hemophilia.
- B. Lymphoma.
- C. Thrombocytopenia.
- D. Trombocytosis.

**Answer: C**

Explanation:

The correct answer to the question regarding what a low platelet count is referred to as is "Thrombocytopenia." This term specifically describes a condition where the blood has an abnormally low number of platelets. Platelets, also known as thrombocytes, are small blood cells essential for normal blood clotting. When injuries occur, platelets clump together to form clots to stop bleeding. In medical terminology, "thrombocytopenia" is derived from three Greek words: "thrombo" (clot), "cyto" (cell), and "penia" (poverty), which collectively translates to a poverty of clotting cells or a deficiency of platelets in the blood. This condition can lead to easy or excessive bruising and bleeding, which can be symptoms to watch for in individuals with suspected low platelet counts. The typical range of platelets in the blood is between 150,000 to 450,000 platelets per microliter (platelets/mcL). When the platelet count falls below 150,000 platelets/mcL, it is considered thrombocytopenia. This threshold helps healthcare providers diagnose and determine the severity of the condition.

The causes of thrombocytopenia are varied and can be grouped into three main categories: reduced production of platelets in the bone marrow (due to factors such as leukemia, certain anemias, viral infections, chemotherapy drugs, and heavy alcohol consumption), increased breakdown of platelets in the bloodstream (from conditions like disseminated intravascular coagulation or certain medications), and increased sequestration of platelets in the spleen (common in liver disease and certain infections). Common risk factors or associated conditions include autoimmune diseases (where the body's immune system mistakenly attacks its own platelets), exposure to toxic chemicals, certain medications that affect platelet production or function, and recent viral infections which can temporarily disrupt bone marrow function. Cancer treatments such as chemotherapy and radiation therapy can also significantly impact platelet counts due to their effects on bone marrow.

In conclusion, understanding thrombocytopenia and its implications is crucial for managing potential risks associated with low platelet counts, such as bleeding disorders. Effective management and treatment depend on diagnosing the underlying cause of the condition, which can range from medication side effects to more severe bone marrow disorders. Regular monitoring and medical consultation are essential for individuals diagnosed with or suspected of having thrombocytopenia.

### Question: 3

About how long does a myocardial biopsy take to complete?

- A. 4-6 hours.
- B. 2-3 hours.
- C. 30 to 60 minutes.
- D. 10 to 15 minutes.

**Answer: C**

Explanation:

A myocardial biopsy, also referred to as a heart biopsy, is a medical procedure that involves the removal of a small piece of heart muscle tissue for examination. This biopsy is typically conducted to diagnose heart conditions or to monitor heart health following a transplant or when other heart diseases are suspected.

The procedure is relatively quick, generally taking about 30 to 60 minutes to complete. During a myocardial biopsy, patients are usually awake. Local anesthesia is applied to numb the area of insertion to minimize discomfort.

The process begins with a small incision made in the patient's arm, groin, or neck, depending on the access point chosen for entry. A catheter, a thin flexible tube, is then inserted into a vein or artery through this incision. The catheter used in this type of biopsy is equipped with a biptome—a tool with a grasping device at the tip designed specifically for taking tissue samples from the heart.

The surgeon or cardiologist manipulates the catheter through the blood vessel to reach the heart. Once positioned correctly, the biptome is used to snip a small piece of heart tissue. This sample is then safely withdrawn with the catheter and sent to a laboratory for analysis. The results can help determine the presence of diseases, assess rejection risk in heart transplant patients, or aid in other diagnostic assessments.

Despite the invasiveness of the procedure, it is generally considered safe when performed by experienced medical professionals. The duration, while relatively brief, allows enough time to both access the heart and retrieve necessary tissue samples without requiring a lengthy recovery period for the patient.

### Question: 4

What is the most common site for a catheter access in an Electrophysiology stimulation?

- A. Subclavian vein.
- B. Femoral vein.
- C. Subclavian artery.
- D. Femoral artery.

**Answer: B**

Explanation:

In electrophysiology studies, which are used to diagnose and treat electrical activities of the heart, accessing the heart via a suitable vein or artery is crucial. Among the various access points available for catheter insertion, the femoral vein stands out as the most commonly utilized site. Located in the groin, this vein offers a direct and relatively straightforward route to the heart, making it a preferred choice for many clinicians.

The choice of the femoral vein is favored due to several practical reasons. First, its large diameter allows easier navigation of catheters, reducing the risk of vessel damage. Second, the anatomical pathway from the femoral vein to the heart is relatively uncomplicated, which facilitates the advancement of catheters into various parts of the heart, including the atria and ventricles. Additionally, the access procedure in the femoral area is well-tolerated by patients and has a lower risk of serious complications compared to other sites.

While the femoral vein is predominant, other vascular access sites like the subclavian vein and the internal jugular vein serve as alternative routes. The subclavian vein, running beneath the collarbone, and the internal jugular vein, located in the neck, are also viable for catheter placement. These sites are sometimes chosen based on specific clinical indications or patient anatomy. However, they come with their own sets of challenges, such as a higher risk of pneumothorax with subclavian vein access and more complex ultrasound-guided access requirements for the internal jugular vein.

Each access site has its advantages and potential complications, and the choice of site may vary depending on the patient's specific medical condition, the type of procedure being conducted, and the physician's expertise and preference. Despite these variables, the femoral vein remains the most

frequently used and generally the safest and most effective site for catheter access in electrophysiology procedures.

### Question: 5

Which of the following diagnostic cardiac procedures assesses the anatomical structures of the aorta and great vessels of the heart?

- A. Aortography
- B. Coronary angiography
- C. Ventriculography
- D. Aortorrhaphy

**Answer: A**

Explanation:

The correct diagnostic cardiac procedure that assesses the anatomical structures of the aorta and the great vessels of the heart is aortography. Aortography is an imaging technique that primarily focuses on the aorta, the largest artery in the body, which carries oxygenated blood from the heart to various parts of the body. This procedure involves the use of X-rays in conjunction with a contrast medium that is injected into the bloodstream. The contrast medium enhances the visibility of the aorta and its branches on the X-ray images, allowing for a detailed assessment of these structures.

During an aortography, the doctor can examine the condition of the aorta and its major branches, including potential issues like aneurysms, blockages, or dissections. This test is vital for diagnosing diseases that affect the aortic arch and the thoracic and abdominal regions of the aorta. The detailed images produced help in planning medical or surgical treatments for aortic diseases.

Other procedures mentioned, such as coronary angiography, ventriculography, and aortorrhaphy, serve different purposes. Coronary angiography is used to visualize the arteries that supply blood to the heart muscle itself, helping in the diagnosis of coronary artery disease. Ventriculography, on the other hand, assesses the function of the heart's ventricles, especially looking at their ability to pump blood and checking for any abnormalities in their movement.

Aortorrhaphy is a surgical procedure rather than a diagnostic test. It involves the suturing of the aorta following an injury or a surgical incision. It is crucial in cases where the integrity of the aorta is compromised, either through traumatic injury or during surgical interventions that involve opening the aorta.

In summary, aortography is the specific procedure among those listed that is designed to assess the anatomical structures of the aorta and the great vessels emanating from the heart. It provides critical information that aids in the diagnosis and management of aortic diseases.

### Question: 6

What are inserted in percutaneous catheterization?

- A. Guide wires.
- B. Inner core.
- C. Spring coil.

D. Fixed core.

**Answer: A**

Explanation:

In percutaneous catheterization, guide wires are used as a crucial tool. These wires serve as a navigating instrument to facilitate the insertion and proper placement of catheters within the vascular system or other ducts in the body. They are especially vital in procedures that require high precision, such as in the case of accessing narrow or tortuous blood vessels.

Guide wires come in various designs, each tailored to specific medical needs or procedural requirements. Some common components of guide wires include the inner core, spring coil, and fixed core. Each of these elements plays a significant role in the functionality of the guide wire.

The inner core of a guide wire is designed to provide stiffness and support while maintaining flexibility. This balance is crucial as it helps the wire navigate through the vascular pathways without causing damage or unnecessary stress to the vessel walls. The inner core can be made from various materials, each selected for its strength, flexibility, and compatibility with the human body.

The spring coil component surrounds the inner core and is primarily responsible for the tactile feedback and pushability of the guide wire. It allows the physician to feel the wire's movement inside the body and make adjustments accordingly. This component is often made of materials that are both resilient and flexible to prevent kinking and to ensure smooth navigation through complex vascular structures.

Some guide wires feature a fixed core, which means the core runs the entire length of the wire. This design provides maximum support and rigidity, which is beneficial in cases where greater force is needed to advance the catheter or when navigating through particularly challenging anatomical pathways. Fixed core guide wires are often used in procedures that require extra stability and precision.

In summary, guide wires in percutaneous catheterization are intricate tools composed of various elements such as an inner core, spring coil, and fixed core. Each component is essential for the guide wire's overall performance, influencing its flexibility, stability, and the level of control a physician has during the procedure. Understanding these components helps in selecting the right type of guide wire for specific medical procedures, ultimately contributing to the success of the intervention and the safety of the patient.

### Question: 7

Capillaries do which of the following?

- A. Connect both the venous and arterial subsystems.
- B. Eliminate bad blood from the body.
- C. Bring oxygen to the brain.
- D. Pump the heart.

**Answer: A**

Explanation:

The circulatory system, a complex network crucial for maintaining bodily functions, comprises four primary subsystems: arterial circulation, venous circulation, capillary circulation, and pulmonary circulation. Each plays a specific role in ensuring the effective transport of blood, oxygen, nutrients, and

waste products throughout the body. Among these, the capillary circulation plays a pivotal role in connecting the arterial and venous subsystems, facilitating a critical exchange process at the microvascular level.

Capillaries, the smallest blood vessels in the body, form a vast network that spans all tissues. These vessels serve as the primary site for the exchange of nutrients, gases, and waste between the blood and body tissues. Structurally, capillaries are distinguished by their extremely thin walls, which consist of a single layer of endothelial cells. This unique construction allows for the efficient and selective transfer of substances across their walls.

The primary function of capillaries is to connect the arterial system, which carries oxygen-rich blood away from the heart to the body, and the venous system, which returns oxygen-depleted blood back to the heart. In this way, capillaries serve as crucial intermediaries that support the continuous circulation of blood. Oxygen and nutrients diffuse out of the capillaries into the surrounding tissues, and waste products like carbon dioxide move from the tissues back into the blood through these tiny vessels. This exchange is vital for maintaining the metabolic balance of the body's various systems. Without capillaries, tissues would not receive the necessary oxygen and nutrients needed for survival, nor would they be able to effectively remove metabolic wastes, which could lead to toxic accumulation and damage. Thus, the role of capillaries extends beyond mere connection of arterial and venous systems; they are integral to the sustenance of life at the cellular level.

### Question: 8

During an thoracic aortography procedure, the anatomical structure that should be included in the imaging is:

- A. Proximal brachiocephalic artery
- B. Abdominal aorta
- C. Superior mesenteric artery
- D. Celiac axis

**Answer: A**

Explanation:

During a thoracic aortography procedure, the primary goal is to visualize the thoracic aorta and its major branches. The thoracic aorta, which extends from the aortic arch down to the diaphragm, is a crucial part of the cardiovascular system as it distributes oxygenated blood to the upper and lower parts of the body via its branches.

One of the key branches that should be included in the imaging during a thoracic aortography is the proximal brachiocephalic artery. This artery is one of the first branches that arise from the aortic arch. It is a vital artery as it eventually bifurcates into the right subclavian artery, which supplies blood to the right arm, and the right common carotid artery, which supplies blood to the right side of the head and neck.

Including the proximal brachiocephalic artery in the imaging is essential for a comprehensive assessment because it helps in evaluating the blood supply to significant areas of the body. Any anomalies, blockages, or diseases affecting this artery can have serious implications, affecting blood flow to the brain and right upper limb. Therefore, visualizing this artery can assist in diagnosing conditions like atherosclerosis, aneurysms, or other vascular diseases.

The other answer choices mentioned – the celiac axis, superior mesenteric artery, and abdominal aorta – pertain to regions primarily below the diaphragm and are not typically visualized in a thoracic aortography. The celiac axis and superior mesenteric artery are major arteries that supply the abdominal organs, and while they are crucial for abdominal assessments, they are not relevant for a thoracic procedure focusing on the chest area.

In conclusion, during a thoracic aortography, the imaging should definitely include the thoracic aorta and its branches like the proximal brachiocephalic artery. This ensures a thorough examination of the arterial supply to the upper part of the body and helps in the accurate diagnosis and management of diseases affecting these regions. Other structures such as the celiac axis, superior mesenteric artery, and abdominal aorta are beyond the scope of this specific imaging study.

## Question: 9

What procedure is described as directly or indirectly connecting the right atrium to the pulmonary artery and closing the atrial defect?

- A. Arterial switch.
- B. Damus-Kaye-Stansel.
- C. Fontan.
- D. Pulmonary artery banding.

**Answer: C**

Explanation:

The correct answer is Fontan. This procedure is specifically designed for treating patients with complex congenital heart defects that involve only one functional ventricle, typically either the left or the right ventricle. The Fontan procedure effectively redirects blood flow from the veins directly to the pulmonary arteries, bypassing the heart. This is achieved by directly or indirectly connecting the right atrium to the pulmonary artery. Additionally, any existing atrial defect, such as an atrial septal defect, is closed during this procedure to ensure proper routing of the blood flow.

In contrast, the Arterial switch operation is used primarily for correcting transposition of the great arteries (TGA), a different congenital heart defect where the main arteries (the aorta and the pulmonary artery) are switched from their normal positions. In this procedure, the aorta is connected to the left ventricle, and the pulmonary artery is connected to the right ventricle, thus correcting the arterial transposition.

The Damus-Kaye-Stansel procedure is another surgical technique used in cases of complex congenital heart defects, particularly when there is an obstruction to the outflow from the ventricles or when transposition of the great arteries is present along with other cardiac anomalies. In this procedure, the pulmonary artery is divided, and one end is connected to the ascending aorta while the other is connected to the right ventricle, facilitating better blood flow from the ventricles.

Lastly, Pulmonary artery banding is a technique used to manage congenital heart defects that result in increased blood flow and pressure to the lungs. This involves placing a band around the pulmonary artery to narrow it, thus reducing the blood flow and pressure within the lungs. This method is often used as a palliative measure or as part of a staged approach to more definitive surgery.

To summarize, the Fontan procedure is characterized by connecting the right atrium directly or indirectly to the pulmonary artery and closing any associated atrial defect, making it the correct answer to the question about the described procedure.

## Question: 10

Ioxaglate belongs to what class of contrast agents?

- A. Ionic monomer.
- B. Non-ionic monomer.
- C. Ionic dimer.
- D. Non-ionic dimer.

**Answer: A**

Explanation:

Ioxaglate falls under the class of ionic dimers. To understand the classification, it's helpful to know some details about contrast agents used in radiology. Contrast agents are substances used to enhance the visibility of internal structures in imaging techniques such as X-rays and CT scans.

Contrast agents are generally categorized based on their ionicity (ionic or non-ionic) and structure (monomer or dimer). Ionic contrast agents contain ions and are further divided into monomers and dimers based on their molecular structure. Monomers have a single triiodinated benzene ring, whereas dimers have two linked triiodinated benzene rings. The presence of these iodine atoms is crucial; they block X-rays and thus enhance the contrast in images.









Ioxaglate, specifically, is an ionic dimer. This means it consists of two linked triiodinated benzene rings, and it contains ions. Ionic dimers are usually linked to radiolucent cations such as sodium and meglumine, which are necessary to balance the charge of the negatively charged iodinated molecules. These cations help make the solution isotonic with blood, reducing the pain and vascular irritation that can occur with hyperosmolar solutions.

The dimeric structure of ioxaglate allows for a lower osmolality compared to monomeric agents, even though it is ionic. Lower osmolality generally results in fewer adverse reactions, which is an advantage in clinical settings, particularly for patients with renal impairment or cardiovascular issues. This property makes ioxaglate a preferred choice in certain diagnostic procedures where high contrast resolution is required without significantly elevating the risk of side effects.

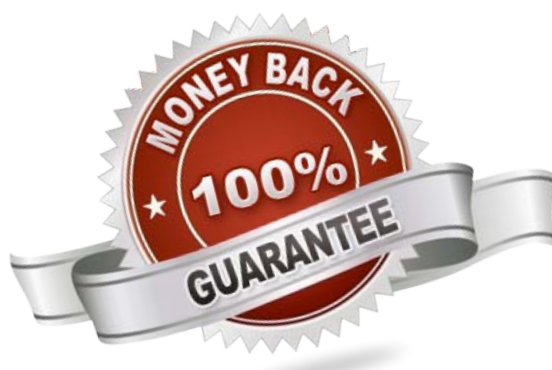
Understanding these properties and differences is vital for choosing the appropriate contrast agent for specific patient needs and diagnostic requirements, ensuring both safety and effectiveness in imaging diagnostics.

For More Information – **Visit link below:**  
<https://www.certsgrade.com/>

## PRODUCT FEATURES

-  **100% Money Back Guarantee**
-  **90 Days Free updates**
-  **Special Discounts on Bulk Orders**
-  **Guaranteed Success**
-  **50,000 Satisfied Customers**
-  **100% Secure Shopping**
-  **Privacy Policy**
-  **Refund Policy**

**16 USD Discount Coupon Code: NB4XKTMZ**



Visit us at: <https://www.certsgrade.com/pdf/ci>