

Healthcare CCI-RCS

CCI Registered Cardiac Sonographer (RCS)

Questions And Answers PDF Format:

For More Information – Visit link below:

<https://www.certsgrade.com/>

Version = Product



Latest Version: 6.0

Question: 1

The technician receives a 70 year old male patient that is scheduled for a cardiac ultrasound. Upon arrival the patient is alert and oriented with vital signs within normal range. Approximately 15 minutes into the procedure, the patient starts to complain of crushing chest pain and becomes diaphoretic. Of the following, which would be considered the first thing the technician should do?

- A. Start CPR
- B. Shock the patient with 360 j
- C. Stop the test and let the patient rest for 15 minutes
- D. Call for help and place oxygen on the patient

Answer: D

Explanation:

In this scenario, a 70-year-old male patient undergoing a cardiac ultrasound experiences sudden symptoms indicative of a possible acute cardiac event—specifically, crushing chest pain and diaphoresis (sweating). These symptoms are highly suggestive of an acute myocardial infarction (heart attack), which is a life-threatening condition requiring immediate medical intervention.

Given the acute presentation of these symptoms, the first and most critical action for the technician is to call for help. This means alerting other healthcare professionals in the facility, such as nurses and doctors, who can provide the necessary medical assistance. Quick response is crucial in such emergencies to maximize the patient's chances of survival and minimize potential heart damage. Simultaneously, placing oxygen on the patient is a vital step. Supplemental oxygen can be beneficial in situations of cardiac distress by increasing the oxygen available for myocardial metabolism, thereby supporting heart function and potentially reducing myocardial injury. Oxygen therapy is a common practice in the management of patients suspected of having a heart attack, although its use should be tailored based on the patient's oxygen saturation levels and clinical condition.

Further interventions might include the administration of medications like aspirin, nitroglycerin, or morphine as guided by the attending physicians based on a rapid assessment of the patient. These medications help in reducing heart workload, improving blood flow, or managing pain, respectively. Advanced Cardiac Life Support (ACLS) protocols may be followed, which include continuous monitoring, further pharmacological treatment, and preparation for potential advanced interventions like defibrillation or cardiopulmonary resuscitation (CPR) if the patient's condition deteriorates leading to cardiac arrest. However, initiating CPR or defibrillation is only indicated if the patient becomes unresponsive or shows signs of life-threatening arrhythmias.

It is not appropriate to shock the patient with a defibrillator unless he is found to have a shockable rhythm as per ACLS guidelines. Similarly, merely stopping the test and allowing the patient to rest is insufficient for addressing the immediate danger posed by a heart attack. Immediate medical intervention is critical in this scenario.

In conclusion, the prompt call for help combined with the application of oxygen and readiness to escalate care according to ACLS protocols represents the most appropriate and immediate set of actions

the technician should undertake when a patient shows symptoms of a potentially severe cardiac event during a procedure.

Question: 2

The Windkessel effect would result in which of the following occurring?

- A. Continued flow in the forward direction
- B. Intermittent flow in the forward direction
- C. No flow in the forward direction
- D. A temporary forward flow followed by a backward flow

Answer: A

Explanation:

*The Windkessel effect is a physiological phenomenon that plays a crucial role in the cardiovascular system, particularly in the dynamics of blood flow and pressure in the large arteries. The term "Windkessel" translates to "air chamber" in German, and the effect describes how elastic arteries help to maintain a relatively constant blood flow during the cardiac cycle, despite the intermittent nature of the heart's pumping. *

*To understand the Windkessel effect, it is important to note that the heart ejects blood into the arteries in a pulsatile manner, which means the blood flow is high during systole (when the heart contracts) and low during diastole (when the heart relaxes). However, the arteries, especially the aorta and its major branches, are elastic and can expand when the blood is pumped into them by the heart. This expansion of the arteries temporarily stores some of the energy from the blood pushed out by the heart. *

*Once the heart relaxes (during diastole), the elastic arteries begin to recoil back to their original shape. This recoil action helps to push the blood forward, maintaining the flow even when the heart is not actively pumping. Essentially, the arteries act like a reservoir and a conduit, ensuring that the blood flow to peripheral tissues remains steady and smooth, rather than pulsatile. *

*The options provided in the question all relate to the direction and continuity of blood flow as influenced by the Windkessel effect: 1. Continued flow in the forward direction: This is the correct outcome of the Windkessel effect. Due to the elastic properties of the arteries and their ability to recoil, blood continues to flow in the forward direction even during the relaxation phase of the heart. 2. Intermittent flow in the forward direction: This would suggest a disruption in the smoothing effect of the Windkessel function, which is not typical unless there are pathological changes in arterial compliance. 3. No flow in the forward direction: This would imply a complete cessation of blood movement post-systole, which contradicts the basic principles of arterial elasticity and recoil facilitated by the Windkessel effect. 4. A temporary forward flow followed by a backward flow: The occurrence of backward flow would indicate a failure in the valve mechanisms (such as aortic regurgitation), which is not a consequence of the Windkessel effect itself. Under normal physiological conditions, the aortic valve closes after systole, preventing any backward flow of blood from the arteries to the heart. *

*Therefore, the correct interpretation and outcome of the Windkessel effect is the continued flow of blood in the forward direction, facilitated by the elastic recoil of the arteries and the proper functioning of cardiac valves, ensuring efficient circulation and distribution of blood throughout the body.

Question: 3

The image processor formats echo data line into image form for all but which of the following?

- A. Display
- B. Storage
- C. Functions
- D. Storage processing

Answer: C

Explanation:

The question you're asking about relates to the functions of an image processor in the context of handling echo data. Echo data, commonly derived from techniques like ultrasound, is converted into a usable form (image form) by an image processor. This conversion is essential for various applications, including medical imaging and sonar technology. The question specifically asks for which function the image processor does not format echo data into image form.

To understand the context better, let's break down the typical functions of an image processor in these scenarios: 1. **Display**: The primary function of converting echo data into image form is for display purposes. For medical diagnostics, real-time imaging is crucial for observing the state of internal organs or tissues. Similarly, in other fields like underwater exploration using sonar, real-time images allow for immediate interpretation and decision-making. 2. **Storage**: Once echo data is converted into images, these images often need to be stored for future reference, further analysis, or maintaining patient records in medical cases. The image format makes it easier to archive and retrieve data efficiently. 3. **Processing**: Beyond mere visualization, echo data images undergo further processing to enhance image quality, extract specific features, or analyze changes over time. Processing can involve filtering, edge detection, and other image enhancement techniques to aid in more accurate interpretation.

Given these functions—Display, Storage, and Processing—it is clear that the image processor necessarily formats echo data into image form for all these purposes. Therefore, any function not listed among these would be the correct answer to the question of which function does not involve formatting echo data into image form. If the question or the choices provided include a function outside these three (such as direct data transmission without formatting, raw data analysis, or any non-visual data application), that would be the correct choice.

Without specific options other than "Display", "Storage", and "Processing" listed in your query, it's challenging to definitively select an 'incorrect' function without more context. If none of the provided options is outside the scope of image formatting, it implies that all given choices are indeed functions for which the image processor formats echo data into image form. Thus, we would need additional information or options to accurately answer the question as posed.

Question: 4

The flow at the entrance of the tube would be considered?

- A. Disturbed

- B. Laminar
- C. Parabolic
- D. Plug flow

Answer: D

Explanation:

When considering the flow of a fluid at the entrance of a tube, it is crucial to understand the type of flow that will be exhibited under various conditions. The type of flow can influence both the efficiency and the dynamics of fluid movement within the tube.

The term "plug flow" refers to a flow condition where the velocity of the fluid is uniform across the cross-section of the tube, except very close to the edges where friction with the tube wall slows the fluid slightly. This means that all elements of the fluid move at the same speed, parallel to the tube axis, and there is no lateral mixing of fluid particles across the direction of flow. Such behavior is often considered ideal and generally observed in tubes under certain conditions, such as low velocities and high viscosities, where the effects of turbulence are minimized.

In terms of practical application, understanding that the flow at the entrance of the tube is plug flow is significant. This is because plug flow ensures a predictable and uniform flow pattern, which is essential in processes where the even distribution of flow properties (like temperature or concentration) is necessary. For example, in chemical reactors, plug flow assures that all reactants have the same residence time and exposure to reaction conditions, leading to consistent product quality.

However, it should be noted that while plug flow might be an ideal condition, actual flow conditions can deviate due to factors such as changes in tube diameter, bends in the tube, roughness of the tube surface, or increased flow rates. These factors can introduce disturbances and lead to the development of other flow profiles, such as laminar or turbulent flow, further along the tube. Laminar flow, characterized by smooth and orderly fluid motion in layers, may develop if the fluid velocity increases or viscosity decreases, while turbulent flow, marked by chaotic fluid motion and mixing, might occur under conditions of high velocity and low viscosity.

In summary, the flow at the entrance of a tube can often be considered as plug flow under ideal conditions. This assumption aids in simplifying analysis and design calculations for various engineering applications where fluid dynamics play a critical role. However, the actual flow type should always be verified, and adjustments should be made as necessary based on the specific operational conditions and the physical characteristics of the fluid and the tube.

Question: 5

Of the following terms, which would be considered the same as the operating frequency?

- A. Transducer frequency
- B. Resonance frequency
- C. Damping frequency
- D. Linear frequency

Answer: B

Explanation:

The operating frequency of a transducer is a fundamental concept in fields such as acoustics, electronics, and signal processing. This frequency is generally referred to as the specific frequency at which a transducer - a device that converts one form of energy into another - operates most efficiently and effectively. It is important in determining how well the transducer will perform its intended function.

Among the terms provided - transducer frequency, resonance frequency, damping frequency, and linear frequency - "resonance frequency" aligns most closely with the operating frequency in the context of transducers. Resonance frequency is defined as the frequency at which a system naturally oscillates at the largest amplitude due to its physical properties. For transducers, operating at or near this frequency ensures maximum energy efficiency and output, as the system requires less energy to achieve higher amplitudes of oscillation.

Transducer frequency could be a general term that sometimes overlaps with operating frequency, but it is not specifically defined as such. It may refer to any frequency at which the transducer can operate, not necessarily the optimum or most efficient one. Damping frequency, on the other hand, relates to the rate at which a system's oscillations decrease over time due to the presence of a damping mechanism, which is different from what is generally sought in defining operating frequency. Lastly, linear frequency is a term not commonly used in this context and does not specifically relate to the properties influencing the efficiency or effectiveness of a transducer's operation.

Therefore, when comparing these terms, resonance frequency is considered equivalent to the operating frequency because it specifically describes the condition under which the transducer's performance is maximized due to natural oscillatory properties. Operating at the resonance frequency helps in achieving optimal performance, making it critical for the design and utilization of efficient transducers.

Question: 6

Which of the following might a transesophageal echocardiogram (TEE) be performed for?

- A. To diagnose diabetes mellitus
- B. To diagnose liver failure
- C. To diagnose blood clots
- D. To diagnose renal failure

Answer: C

Explanation:

A transesophageal echocardiogram (TEE) is a specialized type of echocardiogram, which is an ultrasound test that uses high-frequency sound waves to create images of the heart. Unlike a standard echocardiogram, the TEE involves inserting a probe with a transducer down the esophagus. Since the esophagus is located close to the heart, this positioning allows for more detailed images of the heart's structures.

A TEE might be performed for several reasons related to diagnosing and assessing conditions affecting the heart. One common reason for performing a TEE is to diagnose blood clots, particularly in the chambers of the heart. Blood clots in the heart can lead to serious conditions such as stroke or pulmonary embolism if they are dislodged and travel to the brain or lungs. By providing a close-up view of the heart's chambers and valves, a TEE can help doctors detect the presence of clots that might not be visible on a regular echocardiogram.

Another important use of the TEE is to diagnose infections of the heart valves, also known as endocarditis. This condition can cause changes in the appearance and function of the heart valves, and a TEE is particularly useful in visualizing these changes. The detailed images produced can help identify abnormalities such as vegetations (clumps of bacteria and cells) on the valve leaflets, which are indicative of infection.

Besides diagnosing blood clots and infected heart valves, TEE is used to assess a variety of other heart-related issues. These can include evaluating the heart's function and structure, examining the effects of valve disease, assessing the severity of certain conditions like aortic stenosis or mitral regurgitation, and guiding cardiac interventions such as valve repair or replacement.

It is important to note that TEE is not used for diagnosing conditions that do not directly involve the heart, such as diabetes mellitus, liver failure, or renal failure. These conditions are typically assessed using other diagnostic tests more specific to the organs involved.

Question: 7

Which of the following symptoms might be considered correct for stage B of valvular aortic stenosis?

- A. Heart failure
- B. Chest pain
- C. Presyncope
- D. None

Answer: D

Explanation:

Valvular aortic stenosis is a progressive condition characterized by the narrowing of the aortic valve, which can impede the flow of blood from the left ventricle to the aorta. This disease is categorized into various stages from A to D, reflecting the progression from risk of developing the disease to advanced symptoms and complications.

Stage A represents patients who are at risk for aortic stenosis. These individuals do not have valvular obstruction but are predisposed to it due to factors such as bicuspid aortic valve or rheumatic heart disease. There are no symptoms in this stage because the valve area is not yet significantly reduced to impair cardiac output.

Stage B is labeled as 'progressive' aortic stenosis. During this stage, patients have developed mild to moderate valve narrowing. Despite the structural changes, individuals in Stage B typically do not exhibit symptoms because the body can often compensate for the reduced valve area, and the cardiac output is maintained at a level that meets the body's needs under normal conditions.

Stage C is divided into two subcategories: C1 (asymptomatic severe aortic stenosis) and C2 (symptomatic severe aortic stenosis). Stage C1 patients have severe valve narrowing but without associated symptoms. When symptoms such as chest pain, syncope, or heart failure appear, the condition progresses to Stage C2. The presence of symptoms at this stage indicates that the heart is struggling to maintain adequate blood flow during increased demands.

Stage D is the final and most severe stage, characterized by severe symptomatic aortic stenosis with signs of heart failure. Patients in this stage experience significant symptoms and are at high risk for adverse outcomes without intervention.

Given this staging, for the question regarding which symptoms might be correct for stage B of valvular aortic stenosis, the answer would be 'None.' Patients in Stage B do not typically exhibit symptoms such

as heart failure, chest pain, or presyncope. These manifestations generally begin in Stage C2 when the stenosis becomes severe enough to significantly hinder cardiac output during increased physical activity or stress. Therefore, the correct understanding of the staging helps in identifying the appropriate clinical management and timing for potential interventions like surgical valve replacement or other therapies.

Question: 8

In which of the following areas would the patient most likely experience pain from an aortic aneurysm?

- A. Lower back
- B. Legs
- C. Head
- D. Feet

Answer: A

Explanation:

An aortic aneurysm is a bulge or swelling in the aorta, the main artery that carries blood from the heart to the rest of the body. Aneurysms can occur anywhere along the aorta, but they are most commonly found in two main areas: the chest (thoracic aortic aneurysm) and the abdomen (abdominal aortic aneurysm). The location of the aneurysm significantly influences the symptoms and where the pain is felt.

If the aneurysm is located in the thoracic region, the patient is more likely to experience pain in the chest. This pain can be sharp or tearing and may radiate to the back or between the shoulder blades. Thoracic aortic aneurysms can also cause other symptoms such as shortness of breath, cough, hoarseness, or difficulty swallowing, depending on the extent of the aneurysm and whether it impacts other structures within the chest.

Conversely, if the aneurysm is in the abdominal section of the aorta, the patient is more likely to experience pain in the lower back, which can sometimes be confused with back problems or kidney pain. This pain might also manifest as a pulsating sensation near the navel or as a constant, deep pain in the abdomen. Abdominal aortic aneurysms can remain asymptomatic until they become large or rupture, at which point they become a medical emergency.

Pain in other areas such as the legs, head, or feet is less likely to be directly associated with an aortic aneurysm. However, severe cases of aortic aneurysm involving extensive dissection or rupture could potentially lead to symptoms affecting the legs, such as claudication (pain caused by too little blood flow during exercise), if the blood flow to these areas is compromised. Pain in the head or feet is generally unrelated to aortic aneurysms and might suggest other medical issues.

Thus, among the options provided—chest, lower back, legs, head, and feet—the most likely area where a patient would experience pain from an aortic aneurysm, particularly if the aneurysm is unspecified, would be the lower back, more common with an abdominal aortic aneurysm. This is because the abdominal aorta is a common site for aneurysms, and the symptoms there are more distinctly noted due to the pain and discomfort they cause.

Question: 9

Of the following, which would be considered a component of the regurgitant color Doppler flow pattern?

- A. The distal jet
- B. The proximal jet
- C. The cava contracta
- D. The distal flow convergence

Answer: A

Explanation:

In the context of color Doppler echocardiography, the regurgitant color Doppler flow pattern is crucial for assessing the severity and nature of regurgitation across heart valves. This pattern is typically analyzed to help understand the dynamics of blood flow that leaks back through valves that should normally prevent such a backward flow. The question focuses on identifying which elements are considered part of this pattern, specifically querying whether 'The distal jet' belongs to this group. To answer this, it is essential to understand the components of the regurgitant color Doppler flow pattern: 1. **The Vena Contracta**: This is the narrowest part of the jet immediately as it exits the regurgitant valve. It represents the cross-sectional area of the regurgitant stream and is a critical measure because its size correlates with the severity of regurgitation. 2. **The Distal Jet**: This is the jet as it appears downstream of the vena contracta in the receiving chamber (like the left atrium in mitral regurgitation or the right atrium in tricuspid regurgitation). The size, shape, and extent of the distal jet provide additional information about the severity and the direction of the regurgitant flow. 3. **The Proximal Flow Convergence**: This occurs on the ventricular side of a regurgitant mitral or tricuspid valve, where blood accelerates and converges as it approaches the regurgitant orifice. The pattern and size here can be analyzed using specific modalities like the Proximal Isovelocity Surface Area (PISA) method to quantify the regurgitation severity.

Given these components, 'The distal jet' clearly forms a part of the regurgitant color Doppler flow pattern. This component is important because it helps in visualizing where and how the regurgitant flow disperses into the receiving chamber, thus playing a role in assessing the impact and extent of the regurgitation.

Therefore, the correct answer to the question of which component is part of the regurgitant color Doppler flow pattern is 'The distal jet'. It is integral to the evaluation of regurgitant lesions in echocardiography and helps in both qualitative and quantitative assessments of valve function. Other options listed, like 'The cava contracta' and 'The distal flow convergence', are not standard terms or recognized components within the accepted framework of echocardiographic assessment of regurgitation.

Question: 10

When there is arterial oxygen desaturation that results from shunting/mixing of systemic venous blood into the arterial circulation, it would be considered?

- A. Peripheral cyanosis
- B. Indirect cyanosis
- C. Desaturated cyanosis
- D. Central cyanosis

Answer: D

Explanation:

The correct answer to the question is central cyanosis. Let's expand on the explanation to better understand why this is the case.

Cyanosis is a physical sign characterized by a bluish discoloration of the skin and mucous membranes. This discoloration occurs due to an increased concentration of deoxygenated hemoglobin in the blood, which is more than 5 grams per deciliter. Cyanosis can be classified into two main types: peripheral and central.

Peripheral cyanosis occurs when there is decreased blood circulation to the extremities such as fingers, toes, and lips. This form of cyanosis is often more noticeable in the fingernails and toenails and can be caused by conditions that lead to vasoconstriction or diminished blood flow, such as cold environments, heart failure, or venous obstruction.

Central cyanosis, on the other hand, indicates a systemic decrease in arterial oxygenation and is typically observed in areas with a high density of blood vessels like the lips, tongue, and oral mucosa. Central cyanosis can result from various pulmonary, cardiac, or hematologic conditions that affect the oxygenation of blood in the lungs or lead to mixing of oxygenated and deoxygenated blood.

In the context of the question, arterial oxygen desaturation resulting from the shunting or mixing of systemic venous blood into the arterial circulation points to a problem where venous blood bypasses the lungs and enters the arterial system without being properly oxygenated. This scenario is typical in certain congenital heart diseases such as ventricular septal defects, atrial septal defects, or conditions like Eisenmenger syndrome.

The shunting can occur either at the level of the heart or between the great vessels, leading to a significant amount of deoxygenated blood entering the systemic circulation, thereby causing systemic hypoxemia and central cyanosis.

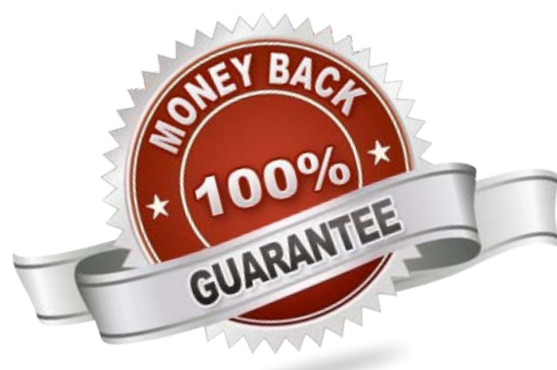
Therefore, in this scenario, where there is a direct mixing of deoxygenated venous blood into the arterial system, the resultant cyanosis is classified as central cyanosis. This type of cyanosis is indicative of a more severe underlying systemic issue and requires prompt medical evaluation and intervention to manage the underlying cause and improve oxygenation.

For More Information – **Visit link below:**
<https://www.certsgrade.com/>

PRODUCT FEATURES

-  **100% Money Back Guarantee**
-  **90 Days Free updates**
-  **Special Discounts on Bulk Orders**
-  **Guaranteed Success**
-  **50,000 Satisfied Customers**
-  **100% Secure Shopping**
-  **Privacy Policy**
-  **Refund Policy**

16 USD Discount Coupon Code: NB4XKTMZ



Visit us at: <https://www.certsgrade.com/pdf/cci-rs>