

# Healthcare CCI-CRAT

## CCI Certified Rhythm Analysis (CRAT)

Questions And Answers PDF Format:

For More Information – Visit link below:  
<https://www.certsgrade.com/>

*Version* = Product



# Latest Version: 6.0

## Question: 1

Which of the following shows the precise sequence of electrical events occurring in the cardiac cells throughout the depolarization-repolarization cycle?

- A. EKG
- B. Ablation
- C. CT scan
- D. Angiography

**Answer: A**

Explanation:

The question you're asking about is focused on identifying which medical tool or procedure accurately displays the sequence of electrical events that occur during the cardiac depolarization-repolarization cycle. To answer this, let's expand on why an electrocardiogram (EKG) is the correct choice among the options provided (EKG, Ablation, CT scan, Angiography).

**EKG** An electrocardiogram (EKG) is a test that is specifically designed to record the electrical activity of the heart over a period. This recording is crucial for understanding the sequence of events that occur during each heartbeat, which includes depolarization and repolarization of the cardiac cells.

Depolarization refers to the electrical activation of the heart cells, leading to cardiac muscle contraction, while repolarization refers to the process by which the heart muscle returns to its resting state.

The EKG works by capturing these electrical signals through electrodes placed on the patient's body. The resulting graph (or EKG tracing) shows several distinct components, each representing different parts of the cardiac cycle: 1. **P wave:** Indicates atrial depolarization. 2. **QRS complex:** Represents ventricular depolarization and the main spike seen on an EKG tracing. 3. **T wave:** Shows ventricular repolarization. This sequence is critical for diagnosing various cardiac conditions, such as arrhythmias, heart block, myocardial infarction, and more. The precise timing and shape of each wave can indicate whether the electrical activity is normal, or if there are disturbances that could suggest underlying heart issues.

**Ablation** While cardiac ablation is a procedure used to treat some types of arrhythmias, it involves using energy to modify small areas of heart tissue that cause abnormal heart rhythms. This procedure itself does not show the sequence of electrical events but rather intervenes in these events to restore normal rhythm.

**CT Scan** A CT scan provides important images that can help diagnose diseases and conditions by producing cross-sectional images of the body using X-rays and a computer. However, it does not provide real-time or dynamic information on the electrical activity of the heart or its depolarization and repolarization cycles.

**Angiography** Angiography is an imaging test that uses X-rays to view your body's blood vessels. While it is crucial for diagnosing and treating vessel-related issues, like blockages or aneurysms, and can provide information about structural heart conditions, it does not offer data about the electrical activity of the heart.

Therefore, among the given options, the EKG is the only tool that accurately and precisely records the sequence of electrical events (depolarization and repolarization) in the cardiac cells. It is essential for diagnosing and monitoring various cardiac disorders related to the electrical function of the heart.

## Question: 2

Simply stretching the outer layer of the skin can produce which of the following?

- A. Large baseline shifts
- B. Electrical signals
- C. asystole
- D. Tachycardia

**Answer: B**

Explanation:

Simply stretching the outer layer of the skin, known as the epidermis, can indeed produce electrical signals. This occurs due to the piezoelectric properties of the skin, where mechanical stress—such as stretching—is converted into electrical energy. The generation of these signals is a result of the structural composition of the skin, including collagen, which is a natural piezoelectric material. When stretched, the rearrangement of the collagen fibers results in the generation of electrical charges, leading to a voltage of several millivolts.

These small electrical signals produced by the skin are often observed as motion artifacts in biometric monitoring systems, such as electrocardiograms (ECGs) and electroencephalograms (EEGs). Motion artifacts can complicate the interpretation of such data because they introduce additional signals that are not related to the physiological parameters intended to be measured. For example, if a patient moves during an ECG recording, the mechanical activity associated with the movement of the skin and underlying tissues can produce these electrical signals, which may be misinterpreted as heart activity. One specific consequence of motion artifacts is the phenomenon known as a large baseline shift. This occurs when there is a significant change in the recorded signal baseline, often due to movements like shifting body positions, tapping on the electrode placement area, or even intense muscle contractions. Large baseline shifts can obscure true physiological signals and make it difficult for healthcare providers to accurately assess heart function or other parameters.

It is important to distinguish between these mechanically-induced signals and true physiological changes. For instance, conditions like asystole (a state of no cardiac electrical activity) and tachycardia (an abnormally fast heart rate) are physiological events that should be identified based on intrinsic electrical activities of the heart, not on artifacts from skin stretching or other movements. Proper electrode placement, stable sensor attachment, and minimal patient movement during measurements are critical to reducing these artifacts and obtaining accurate physiological data.

## Question: 3

Which of the following is not a cause of ventricular fibrillation?

- A. Myocardial ischemia
- B. Overheating

- C. Electric shock
- D. Electrolyte imbalance

**Answer: B**

Explanation:

Ventricular fibrillation (VF) is a serious cardiac rhythm disturbance where the electrical activity of the ventricles becomes so chaotic that the heart ceases to pump effectively, leading to sudden cardiac arrest. This condition is life-threatening and requires immediate medical intervention to restore a stable heart rhythm. Several factors can precipitate ventricular fibrillation, and understanding these causes helps in both prevention and treatment.

Among the known precipitants, myocardial ischemia stands out as a significant cause. Myocardial ischemia occurs when the blood flow to a part of the heart muscle (myocardium) is obstructed, usually by a partial or complete blockage of the heart's coronary arteries. This reduced blood flow can lead to heart muscle damage and electrical instability, which in turn can trigger ventricular fibrillation.

Other well-established causes of ventricular fibrillation include myocardial infarction (a complete blockage of coronary arteries leading to heart muscle death), untreated ventricular tachycardia (a rapid heart rhythm originating from the ventricles), severe hypothermia (abnormally low body temperature), electric shock, certain drug toxicities (such as from overdoses of medications or illicit drugs), electrolyte imbalances (particularly abnormalities in potassium or magnesium levels), severe hypoxia (low oxygen levels in the blood), acid-base imbalances, and underlying heart diseases such as cardiomyopathies.

However, overheating, or hyperthermia, is typically not listed among the direct causes of ventricular fibrillation. While extreme body temperatures can lead to serious health issues, including heat stroke and multi-organ failure, the direct induction of ventricular fibrillation by overheating alone is not commonly recognized in medical literature. It's more likely that complications stemming from prolonged hyperthermia could contribute to conditions that might indirectly increase the risk of ventricular fibrillation, such as electrolyte imbalances or exacerbated underlying heart conditions. Therefore, overheating is not a direct cause of ventricular fibrillation, unlike the other factors mentioned.

In summary, while many physiological disturbances can precipitate ventricular fibrillation, overheating is not typically recognized as a direct cause. This distinction is crucial in medical settings for prioritizing preventive measures and treatments that specifically address the direct causes of ventricular fibrillation.

### Question: 4

Which of the following should not be performed on reusable equipment following a procedure?

- A. Discard equipment promptly
- B. Clean thoroughly
- C. Disinfect
- D. Sterilize

**Answer: A**

Explanation:

The correct answer to the question asking which action should not be performed on reusable equipment following a procedure is "Discard equipment promptly." This practice is inappropriate for reusable

medical equipment, which is designed to be used multiple times. Proper care and handling of such equipment are crucial to prevent the spread of infections and ensure the safety and well-being of patients.

Reusable medical equipment must undergo a stringent cleaning, disinfection, and sterilization process after each use. This is necessary because during medical procedures, equipment often comes into contact with secretions, excretions, bodily fluids, or blood, which can contain harmful microorganisms. If not properly treated, these contaminants can pose a risk of infection to other patients.

The first step in reprocessing reusable equipment is thorough cleaning, which removes visible dirt and reduces the amount of organic matter that can protect microorganisms from the disinfection process. Following cleaning, the equipment undergoes disinfection, which involves using chemicals or physical methods to kill many or all pathogenic microorganisms, except bacterial spores.

Sterilization is the final step, which is more rigorous than disinfection. This process kills all forms of microbial life, including bacterial spores, and is required for equipment that comes into contact with sterile body regions or vascular systems.

In contrast, single-use equipment is designed to be used once and then discarded. This is primarily for items that cannot withstand the cleaning, disinfection, and sterilization processes or where the cost of reprocessing exceeds the cost of replacement. Discarding these items promptly after use helps prevent potential cross-contamination between patients and simplifies the workflow in healthcare settings. Thus, discarding reusable equipment promptly would be a significant error, leading to unnecessary waste of resources and potential harm to patients due to equipment shortages or inadequate sterilization. Instead, it is essential to follow the proper reprocessing protocols to ensure that all reusable equipment is safe for future use.

### Question: 5

If a patient is having a stress test and starts to complain of dizziness, which of the following would be considered the first intervention the technician should take?

- A. Report the situation to the physician
- B. Send the patient home and tell him to call his physician
- C. Have the patient lie flat for 15 minutes and attempt the test a second time.
- D. Stop the test

**Answer: D**

Explanation:

When conducting a stress test, patient safety is the primary concern. A stress test typically involves physical exercise or pharmacological stimulation to evaluate the heart's response under stress. If a patient starts to complain of dizziness during the test, it is crucial to immediately address potential complications such as cardiovascular instability or an adverse reaction to the test.

The first intervention a technician should take if a patient reports dizziness during a stress test is to stop the test. Dizziness can be an indicator of several serious conditions, such as low blood pressure, arrhythmia, or ischemia (reduced blood flow to the heart). Continuing the test could exacerbate the patient's condition and lead to more severe health issues.

Once the test is halted, the technician should then assist the patient to a safe, resting position and promptly perform an initial assessment. This includes checking vital signs like blood pressure and heart

rate, and observing for any other symptoms such as chest pain or shortness of breath. It is important to gather this information to provide a clear picture of the patient's condition to the attending physician. After assessing the patient, the next step is to notify the physician. The physician can then evaluate the patient's symptoms and vital signs to determine the cause of the dizziness and decide on the appropriate medical intervention. This might include further diagnostic tests or treatments depending on the underlying issue identified.

Other options, such as sending the patient home, having the patient lie flat for a period, or attempting the test again, are inappropriate first responses without physician assessment and clearance. These actions could potentially delay necessary immediate treatment and lead to worsening of the patient's condition. Thus, the priority is to stop the test, assess the situation, and seek physician guidance to ensure patient safety and effective medical care.

### Question: 6

The T wave's peak represents which of the following?

- A. Relative refractory period of ventricular repolarization
- B. End of ventricular depolarization
- C. End of ventricular conduction
- D. Presence of myocardial infarction or ischemia

**Answer: A**

Explanation:

The T wave on an electrocardiogram (ECG) is a crucial component in the analysis of cardiac function. It primarily represents the process of ventricular repolarization, which is when the ventricles of the heart recover their resting electrical state following a contraction. More specifically, the peak of the T wave marks a significant phase within this repolarization process known as the relative refractory period. During the relative refractory period, the cardiac cells are partially recovered from the prior electrical excitation and can potentially be re-excited with a stronger-than-normal stimulus. This phase is critical because it represents a state of increased vulnerability where premature cardiac beats can occur if additional stimuli are present. Such premature beats can lead to arrhythmias, which are irregular heart rhythms that can range from benign to life-threatening.

It is important to note that the morphology of the T wave, including its symmetry and slope, can provide additional insights into cardiac health. Typically, the T wave is slightly asymmetrical with a more gradual incline and a steeper decline. Any deviation from this pattern can be indicative of underlying cardiac issues, such as electrolyte imbalances, myocardial ischemia, or other cardiac pathologies.

The T wave does not indicate the end of ventricular depolarization; rather, it follows the QRS complex, which actually represents ventricular depolarization. Also, it does not specifically mark the end of ventricular conduction. While alterations in the T wave can sometimes suggest myocardial infarction or ischemia, the peak of the T wave itself directly points to the relative refractory period during the repolarization phase.

In summary, the peak of the T wave is significant as it represents the relative refractory period of ventricular repolarization. Understanding this aspect of the ECG can help in diagnosing and managing potential cardiac conditions effectively by recognizing the periods when the heart is most susceptible to abnormal rhythms.

### Question: 7

Roadblocks with communication is often caused by which of the following?

- A. Effective communication
- B. Poor communication
- C. Both A and B
- D. None of the above

**Answer: B**

Explanation:

Effective communication is crucial in any organization to ensure smooth operations and to facilitate the achievement of business goals. Communication roadblocks, often referred to as bottlenecks, can severely disrupt the flow of information and thus impede progress. Here, we delve into why poor communication often causes these roadblocks.

Firstly, poor communication can stem from a lack of clarity in conveying messages. When information is not clearly communicated, misunderstandings can occur, leading to errors and delays. For instance, if instructions given to complete a task are ambiguous, the recipient may not perform it as expected, resulting in inefficiencies and frustration on both ends.

Additionally, poor communication can result from inadequate channels of communication between departments. If there isn't a reliable system in place that allows for easy and quick sharing of information, departments can become siloed, creating a bottleneck. An example of this is when one department needs timely information or action from another to proceed with a project, and the lack of a robust communication channel delays the entire process.

Communication styles and cultural differences can also contribute to roadblocks. In diverse workplaces, the variance in communication preferences and interpretations can lead to miscommunications unless there is an active effort to understand and adapt to differing communication norms.

Moreover, the absence of feedback mechanisms can create communication roadblocks. Without feedback, misunderstandings or issues may go unresolved, and opportunities for improvement may be missed. Effective communication entails not just sending information but also confirming that it has been understood and acted upon correctly.

In conclusion, roadblocks in communication mainly stem from poor communication practices, which can range from unclear messaging and inadequate communication channels to ignoring cultural differences and lacking feedback loops. Addressing these issues requires a proactive approach to improve communication strategies and tools across departments, ensuring that all team members are on the same page and can collaborate effectively.

### Question: 8

To assess for multifocal atrial tachycardia, the technician must see which of the following on the rhythm strip?

- A. Regular rhythm
- B. At least three different P wave shapes

- C. Normal T waves
- D. Regular PR intervals

**Answer: A**

Explanation:

To correctly assess for multifocal atrial tachycardia (MAT) on a rhythm strip, the most crucial finding a technician must identify is the presence of at least three different P wave shapes. This characteristic is fundamental in distinguishing MAT from other types of arrhythmias. Here's an expanded explanation of why this feature is important and what it indicates about the underlying cardiac activity:

Multifocal atrial tachycardia is a type of irregular cardiac rhythm characterized by multiple ectopic foci firing within the atria, leading to an irregular atrial rate. Since each focus generates its own electrical impulse, the appearance of the P waves — which represent atrial depolarization — varies depending on the origin of the atrial impulse. The presence of at least three different P wave shapes on the EKG indicates that the electrical signals are being generated from multiple locations within the atria, which is a hallmark of MAT.

In addition to noting the variability in P wave morphology, other characteristics associated with MAT include:

- **Irregular atrial and ventricular rhythms:** The rhythm is irregular both because of the varying P wave shapes and because the timing of atrial depolarization changes depending on which ectopic focus dominates.
- **Atrial and ventricular rates between 100-250 bpm:** The atrial rate is usually elevated because multiple foci are active, though ventricular rate can vary based on AV nodal conduction.
- **Variable PR intervals:** The PR interval may vary because each atrial depolarization originates from a different focus, affecting the time it takes the impulse to travel to the ventricles.
- **Normal QRS complexes:** Despite the irregularity in atrial activity, the QRS complexes usually remain normal as the ventricular depolarization is typically not affected.
- **Distorted T waves and Indiscernible QT intervals:** These can occur due to the irregular timing of atrial depolarization affecting the overall cardiac cycle.

It is important for technicians to accurately identify these features on an EKG because MAT can be associated with significant cardiac conditions such as chronic obstructive pulmonary disease (COPD), coronary artery disease, or electrolyte imbalances. Effective identification helps in diagnosing the underlying condition and guiding appropriate treatment strategies.

In summary, the presence of at least three different P wave shapes on a rhythm strip is a key diagnostic criterion for multifocal atrial tachycardia. This finding, along with other EKG characteristics, helps differentiate MAT from other arrhythmias, thereby facilitating appropriate clinical interventions.

## Question: 9

Deep, wide Q waves may indicate which of the following on an ECG?

- A. Bundle branch block
- B. Ventricular conduction delay
- C. Ventricular standstill
- D. Myocardial infarction

**Answer: D**

Explanation:

Deep, wide Q waves on an electrocardiogram (ECG) are significant markers that can indicate a myocardial infarction (MI), commonly known as a heart attack. When part of the heart muscle dies due to lack of blood supply, the electrical patterns that the heart emits change. This ischemic damage to the heart muscle alters the initial part of the QRS complex on an ECG, leading to the formation of deep and wide Q waves.

The presence of Q waves typically suggests that there has been some permanent cardiac muscle damage. In the context of a myocardial infarction, these Q waves are referred to as "pathological Q waves." They become visible within hours or days after the onset of an MI and can remain indefinitely as a sign of the infarcted (dead) myocardium. Pathological Q waves are typically more than 40 milliseconds wide and deeper than 25% of the subsequent R wave's height.

It's important to differentiate these findings from other ECG features that may suggest different cardiac issues: - A notched R wave may signify a bundle branch block, where there is a delay or blockage in the pathway that sends electrical impulses to either the left or right side of the heart's ventricles. - A widened QRS complex often points to a ventricular conduction delay, indicating that the electrical impulse is taking longer than normal to pass through the ventricles. - A missing QRS complex can suggest more severe problems such as ventricular standstill or an atrioventricular (AV) block, where the conduction between the atria and the ventricles is impaired or absent.

Therefore, while deep, wide Q waves are most commonly associated with myocardial infarction, understanding the full context of the ECG and correlating it with patient symptoms and history is crucial for accurate diagnosis and appropriate management of any cardiac event.

## Question: 10

A sequential pacemaker stimulation of the atria and then both ventricles is known as which of the following?

- A. Atrioventricular sequential pacing
- B. Atrioventricular delay
- C. Atriobiventricular pacing
- D. Inherent rhythm

**Answer: C**

Explanation:

**\*\*Atrioventricular sequential pacing\*\*** refers to a pacing technique where the pacemaker first sends an electrical impulse to the atria and then, after a short delay, sends an impulse to the ventricles. This delay, known as the atrioventricular delay, allows for the proper filling of the ventricles following atrial contraction, which is essential for efficient cardiac function.

However, the question specifically mentions the stimulation of both ventricles, which indicates a more specialized form of pacing known as **\*\*Atriobiventricular pacing\*\***. This technique is designed to improve the coordination of the ventricular contractions, particularly in patients with heart failure, where the normal synchronous contraction of the ventricles may be disrupted.









In **\*\*Atriobiventricular pacing\*\***, the pacemaker stimulates the atria first, similar to atrioventricular sequential pacing, but it differs in that it stimulates both the left and right ventricles almost simultaneously. This biventricular pacing helps in resynchronizing the ventricles, which can be particularly beneficial in conditions like left bundle branch block or other forms of dyssynchrony. By

ensuring that both ventricles contract more uniformly, this pacing can enhance the overall cardiac output and efficiency, potentially improving symptoms and quality of life in patients with advanced heart failure.

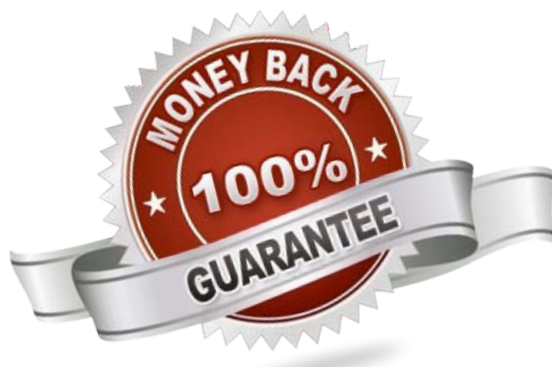
The use of **Atrioventricular pacing** is a part of cardiac resynchronization therapy (CRT), which is aimed at improving the heart's efficiency and reducing heart failure symptoms. This therapy is typically reserved for patients who have not responded adequately to medical therapy alone and exhibit specific patterns of heart dysfunction that are amenable to this type of pacing.

For More Information – **Visit link below:**  
<https://www.certsgrade.com/>

## PRODUCT FEATURES

-  **100% Money Back Guarantee**
-  **90 Days Free updates**
-  **Special Discounts on Bulk Orders**
-  **Guaranteed Success**
-  **50,000 Satisfied Customers**
-  **100% Secure Shopping**
-  **Privacy Policy**
-  **Refund Policy**

**16 USD Discount Coupon Code: NB4XKTMZ**



Visit us at: <https://www.certsgrade.com/pdf/cci-crat>