

Medical Technology HT

Histotechnician Certification Examination Exam

Questions And Answers PDF Format:

For More Information – Visit link below:

<https://www.certsgrade.com/>

Version = Product



Latest Version: 6.0

Question: 1

The process by which a section is purposely overstained and then differentiated in acid alcohol is referred to as the following:

- A.regressive staining
- B.progressive staining
- C.basic staining
- D.counter staining

Answer: A

Explanation:

Hematoxylins can be used either regressively or progressively. Regressive staining refers to when a section is purposely overstained and then differentiated in an acid alcohol to remove some of the stain. Progressive staining refers to when staining of a section is stopped once the desired intensity is achieved, allowing the nuclei to stain adequately but leaving the background tissue relatively unstained.

Question: 2

Mayer hematoxylin is chemically ripened with which of the following oxidants?

- A.Mercuric iodate
- B.Iodine
- C.Potassium iodate
- D.Sodium iodate

Answer: D

Explanation:

Hematoxylin itself is not a stain. It first must be oxidized to become hematein before it can be used as a stain. Hematoxylin can be oxidized naturally through exposure to light and air, but this process can take as long as 3 to 4 months. Hematoxylin can also be oxidized chemically using chemicals such as sodium iodate or mercuric oxide. Chemical oxidation occurs almost instantaneously.

Question: 3

When a blood smear is stained using Wright stain, which of the following white blood cells demonstrates a multi-lobed nucleus and has red-orange granules throughout the cytoplasm?

- A.Basophil
- B.Eosinophil
- C.Lymphocyte
- D.Monocyte

Answer: B

Explanation:

The Wright stain is a modified version of the Romanowsky stain. It is primarily used to differentiate blood cell types. It can also be used for chromosome analysis in cytogenetics studies. Eosinophils demonstrate a multi-lobed nucleus and red-orange granules throughout the cytoplasm when stained using Wright's stain. Basophils, lymphocytes, and monocytes demonstrate nuclei with only one lobe.

Question: 4

Which of the following can be used to differentiate live versus dead cells?

- A.Hematoxylin
- B.Trypan blue
- C.Eosin
- D.Celestine blue

Answer: B

Explanation:

Trypan blue can pass through the membrane of dead cells, but it is excluded from live cells. Therefore, trypan blue can be used to determine cell viability; dead cells appear blue, whereas live cells remain clear.

Question: 5

Rhodamine and fluorescein isothiocyanate (FITC) are both examples of_____.

- A.antibodies
- B.antigens
- C.fluorochromes
- D.enzymes

Answer: C









Explanation:

Fluorochromes are dyes that can be conjugated to antibodies, which can then be used to fluorescently label specific targets in tissues or cells by

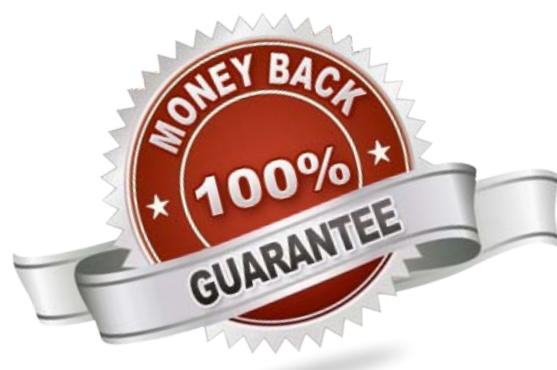
immunohistochemistry. This labeling can then be viewed by fluorescence microscopy or flow cytometry.

For More Information – **Visit link below:**
<https://www.certsgrade.com/>

PRODUCT FEATURES

-  **100% Money Back Guarantee**
-  **90 Days Free updates**
-  **Special Discounts on Bulk Orders**
-  **Guaranteed Success**
-  **50,000 Satisfied Customers**
-  **100% Secure Shopping**
-  **Privacy Policy**
-  **Refund Policy**

16 USD Discount Coupon Code: NB4XKTMZ



Visit us at: <https://www.certsgrade.com/pdf/ht>