

Nursing

*ANCC-FNP-BC
Family Nurse Practitioner Board Certification*

Questions And Answers PDF Format:

**For More Information – Visit link below:
<https://www.certsgrade.com/>**

Version = Product



Latest Version: 6.0

Question: 1

An adult patient needs treatment for Chlamydia trachomatis urethritis. Which one of the following drugs is useful as a single-dose regimen?

- A. Ceftriaxone intramuscularly.
- B. Levofloxacin.
- C. Azithromycin.
- D. Doxycycline.

Answer: C

Explanation:

Only azithromycin has shown effectiveness when taken as a single dose for treatment of chlamydia] urethritis. Levofloxacin and doxycycline are also effective treatment choices, but would have to be taken for seven days. Ceftriaxone (Rocephin) is not effective in this case.

Question: 2

A patient who gave birth to an infant two months previously seems disengaged and withdrawn. The family nurse practitioner is concerned that the patient may have postpartum depression. Which three of the following symptoms are characteristic of postpartum depression?

- A. Insomnia or hypersomnia.
- B. Disorientation and confusion.
- C. Feeling of worthlessness or inadequacy.
- D. Poor concentration and inability to make decisions.
- E. Delusions associated with the infant.

Answer: A,C,D

Explanation:

A patient who has given birth within the previous two to three months and seems disengaged and withdrawn may be exhibiting signs of postpartum depression. Characteristic symptoms include:

- Insomnia or hypersomnia.
- Feeling of worthlessness or inadequacy.
- Poor concentration and ability to make decisions.
- Lack of interest and pleasure.
- Recurrent thoughts of death.
- Lack of energy and constant fatigue.

- Marked change in appetite.
- Consistently sad or depressed mood.

Postpartum psychosis often begins early and is more acute and dangerous and can include disorientation, confusion, hallucinations, and delusions associated with the infant.

Question: 3

A child with fetal alcohol syndrome (FAS) is likely to exhibit which one of the following findings?

- A. Growth deficiency.
- B. Normal IQ.
- C. Thickened upper lip.
- D. Macrocephaly.

Answer: A

Explanation:

FAS is caused by alcohol consumption during pregnancy. Pregnant women should be counseled against drinking any amount of alcohol because there is no known "safe" amount to drink. Pregnant women should abstain from alcohol during all trimesters. Alcohol has a wide range of permanent effects on children, particularly on the nervous system. Some common characteristics include abnormal facial features (thin upper lip and smooth philtrum), microcephaly, growth deficiency, hyperactivity, learning disabilities, and low IQ.

Question: 4

To evaluate a child for esotropia, which one of the following is a rapid and convenient diagnostic screening test?

- A. Slit lamp examination.
- B. Corneal light reflex test.
- C. Snellen test.
- D. Fluorescein test.

Answer: B

Explanation:

Corneal reflex tests are useful to diagnose strabismus (e.g., esotropia). To perform the test, shine a light directly onto both corneas at the same time with the patient looking straight at the light source. In patients with strabismus, the light reflected on the cornea appears off-center in the affected eye. Note that corneal light reflex tests may not detect an intermittent strabismus.

Question: 5

According to Dr. Elisabeth Kubler-Ross, dying patients experience several emotional stages during terminal illness. Which one of these emotions persists throughout all the stages of terminal illness?

- A. Anger.
- B. Hope.
- C. Denial.
- D. Bargaining.

Answer: B

Explanation:

The five emotional stages of dying are hope, denial, isolation, anger, and bargaining. The hope of a cure (even if slim) persists throughout all the other stages of terminal illness. Isolation and denial help handle the shock of approaching death. After this, the patient experiences anger followed by bargaining.

Question: 6

A family nurse practitioner is assessing an 11-month-old African-American child who was brought in by his mother for concerns about swelling in both hands and both feet. On examination, the nurse practitioner finds tenderness and obvious swelling of the hands and feet. Vital signs, including temperature and blood pressure, are normal. The most likely diagnosis is:

- A. osteomyelitis.
- B. hand-foot-mouth disease.
- C. glomerulonephritis.
- D. sickle cell disease.

Answer: D

Explanation:

Dactylitis (hand-foot syndrome) is often the first manifestation of sickle cell disease in an infant or toddler. Swelling and pain are usually symmetric and result from ischemia of small bones.

Bone marrow is expanding and compromising circulation to the bones of the hands and feet. X rays are not helpful in the acute phase, but they eventually show bone destruction and repair.

Management includes hydration and pain control. Patients who present with dactylitis before 24 months of age often go on to have a severe course of sickle cell disease.

Question: 7

A 65-year-old woman complains of urinary incontinence. She is experiencing leakage of urine when she coughs, sneezes, or laughs. This form of urinary incontinence is called:

- A. stress incontinence.
- B. urge incontinence.
- C. overflow incontinence.
- D. functional incontinence.

Answer: A

Explanation:

Stress incontinence refers to leakage of urine by performance of an activity that puts pressure on the bladder. These activities include laughing, sneezing, lifting something heavy, or coughing.

Urge incontinence is present when a patient develops a sudden, strong urge to urinate and begins passing urine before making it to the bathroom. Patients who have functional incontinence have a physical or mental disability that prevents normal urination even though the urinary tract is normal. Examples are Parkinson's disease, dementia, and severe depression.

Question: 8

A full-term newborn weighed 7 pounds, 9 ounces at birth. Three days after hospital discharge, the family nurse practitioner is seeing the baby for his first checkup. He now weighs 7 pounds, 4 ounces. This level of weight loss is:

- A. worrisome because it is below birth weight.
- B. Indicative of inadequate nutrition.
- C. A sign of dehydration.
- D. Normal at this age.

Answer: D

Explanation:

Most babies lose several ounces during the first week of life. They usually get back to birth weight and start gaining weight by two weeks of age. Breastfed babies may take a little longer to get back to birth weight. A weight loss of between 5% and 10% in the first week is within normal range.

Question: 9

Which of the following drugs is NOT associated with human teratogenicity?

- A. Valproic acid.
- B. Warfarin.
- C. Phenytoin.
- D. Amoxicillin.

Answer: D

Explanation:

Valproic acid (Depakene, Depakote) is an anticonvulsant associated with an elevated risk of neural tube defects, such as spina bifida and meningocele, among others. Phenytoin (Dilantin) affects the developing fetus and may cause such defects as cleft lip, cleft palate, mental deficiency, and hypoplastic fingers and nails. Warfarin (Coumadin), a common anticoagulant, is known to cause nasal deformities, brain abnormalities, and stillbirth. Of the answer choices given for this question, only amoxicillin is not known as a teratogen.

Question: 10

The family nurse practitioner is assessing an infant for indications of developmental hip dysplasia utilizing the Ortolani-Barlow maneuver. The maneuver begins by placing the infant on the back and includes the following steps:

1. Grasp the infant's knees with the thumbs over the inner thighs.
2. Slowly abduct the infant's hips and observe for equal movement, resistance, or an abnormal "clunk" sound.
3. Flex the infant's knees and hips to 90 degrees.
4. Touch the infant's knees together, and then press down on the one femur at a time, observing for dislocation. Place the steps to this maneuver in sequential order, from first to last:

- A. 1, 2, 3, 4
- B. 1, 3, 2, 4
- C. 1, 4, 2, 3
- D. 1, 3, 4, 2

Answer: D

Question: 11

An adolescent patient presents with severe sore throat, fever, cervical lymphadenopathy, and difficulty opening the mouth. On examination, the family nurse practitioner sees that the uvula is deviated from the midline and there is some bulging of the soft palate near the tonsillar area. What is the most likely diagnosis?

- A. Epiglottitis .
- B. Viral pharyngitis.
- C. Peritonsillar abscess.
- D. Retropharyngeal abscess.

Answer: C

Explanation:

Peritonsillar abscesses are typical in teens. Symptoms include sore throat, fever, and difficulty swallowing and opening the mouth (trismus). In fact, the exam may be difficult due to trismus. The abscess causes bulging of the soft palate in the tonsillar area. Cultures usually grow group A strep and mixed anaerobes. Retropharyngeal abscesses occur most frequently in children under five years of age and are less common in older patients whose retro pharyngeal nodes have involuted. Epiglottitis also causes sore throat and fever, but it is accompanied by respiratory distress and typically occurs in younger children.

Question: 12

Most cases of infectious pharyngitis are caused by:

- A. viruses.
- B. group A streptococcus.
- C. streptococcus pneumoniae.
- D. haemophilus influenzae.

Answer: A

Explanation:

Viruses cause over 62% of infectious pharyngitis. The remaining answer choices are bacterial agents. Contrary to what patients often believe, group A strep pharyngitis is significantly less common than viral pharyngitis.

Question: 13

A pediatric patient has a tender, boggy lesion on the scalp. There are numerous pustules overlying the lesion. Occipital lymphadenopathy is also present, and there are also three to four small scaly areas of hair loss scattered over the scalp. A Wood's lamp examination shows no fluorescence. What is the most likely diagnosis?

- A. Scalp abscess.
- B. Tinea capitis.
- C. Impetigo.
- D. MRSA infection.

Answer: B

Explanation:

This patient has tinea capitis. The boggy lesion on the scalp is a kerion, which is often mistaken

for an abscess. Itchy, scaly areas on the scalp and scattered areas of hair loss are common, as are swollen occipital lymph nodes. Most cases of tinea capitis in the United States are caused by *Trichophyton tonsurans*, which does not fluoresce on Wood's lamp examination. While impetigo can occur on the scalp, it is not associated with hair loss. All clinical information provided in this clinical scenario points to tinea capitis, making all other choices incorrect.

Question: 14

Which one of the following is a typical characteristic of *Mycoplasma pneumoniae* infection?

- A. Consolidated infiltrate on chest x-ray.
- B. Headaches.
- C. Hypoxia.
- D. Myositis.

Answer: B

Explanation:

Constitutional symptoms such as malaise and headaches are typical with *Mycoplasma pneumoniae* infection. The expected norm for chest x-ray findings is diffuse infiltrates as opposed to a consolidated infiltrate. Myalgias and myositis are more common with viral pneumonia. Hypoxia is also atypical for pneumonia due to *Mycoplasma pneumoniae*.

Question: 15

Thelarche begins in girls during which Tanner stage?

- A. Stage I.
- B. Stage II.
- C. Stage III.
- D. Stage IV.

Answer: B

Explanation:

Breast bud development (thelarche) starts during Tanner stage II. Stage I represents preadolescent girls who have not yet developed secondary sex characteristics. Stages III and IV are more advanced stages of sexual development. Stage V is the highest level of sexual development and is equivalent to an adult in sexual characteristics.

Question: 16

A nurse practitioner is examining a 55-year-old diabetic man who reports a bilateral pretibial rash. The physical exam reveals a thin epidermis with brown-yellow ulcerated plaques that are oozing blood. What is the most likely diagnosis?

- A. Erythema nodosum.
- B. Myxedema.
- C. Cutaneous Candida albicans infection.
- D. Necrobiosis lipoidica diabetorum (NLD).

Answer: D

Explanation:

NLD is characterized by collagen degeneration, granulomatous reaction, fat deposits, and thickened blood vessel walls. The specific cause is unknown, but several theories hint at peripheral blood vessel disease, vasculitis, or trauma. Erythema nodosum usually also occurs on the pretibial areas, but consists of tender red subcutaneous nodules. Myxedema is a non pitting edema associated with hypothyroidism. Candida infections most commonly occur in warm, moist skin folds.

Question: 17

Red blood cell (RBC) casts in the urine indicate:

- A. interstitial nephritis.
- B. myoglobinuria.
- C. renal tubular damage.
- D. glomerular disease.

Answer: D

Explanation:

Urinary casts may be composed of red blood cells, white blood cells, or renal cells. To perform a test for casts, the patient provides a midstream clean-catch urine specimen. RBC casts indicate bleeding into the renal tubule, commonly seen in glomerular diseases such as lupus nephritis, IgA nephropathy, and Wegener's granulomatosis. With renal tubular damage, renal tubular epithelial cell casts are present in the urine. Neither UTIs nor interstitial nephritis is associated with RBC casts.

Question: 18

Which of the following is NOT a criterion for diagnosis of diabetes mellitus?

- A. Fasting blood glucose > 126 mg/dL.
- B. HgA1c of 6.5%.
- C. Polydipsia and polyuria.
- D. Nonfasting blood glucose > 200 mg/dL.

Answer: B

Explanation:

A fasting blood glucose > 126 mg/dL, polydipsia/polyuria, and a nonfasting blood glucose of > 200 mg/dL are all criteria for diagnosing diabetes. HgA1c is useful for periodic assessment of average glucose levels. It is not recommended for diagnostic purposes.

Question: 19

According to federal law, a family nurse practitioner can care for nursing home patients under which of the following conditions?

- A. A physician must be available for emergencies.
- B. Patients must be younger than 80 years of age.
- C. The caseload must not exceed five patients.
- D. All of the above.

Answer: A

Explanation:

A nurse practitioner can care for nursing home patients as long as a physician is available in case of emergency. There are no age restrictions for a FNP's patient population, nor is there a caseload limit.

Question: 20

The public health department has noted a recent increase in cases of West Nile fever, and the family nurse practitioner has begun to see patients with the infection. Which three of the following signs or symptoms does the family nurse practitioner recognize as being typical of West Nile fever?

- A. Alterations of consciousness.
- B. Weakness of facial muscles.
- C. Transient maculopapular rash on the chest, stomach, and back.
- D. Fever, headache, and body aches.
- E. Nausea and vomiting.
- F. Seizures.

Answer: C,D,E









Explanation:

West Nile infections are classified as viremia, West Nile fever, or West Nile encephalitis/meningitis, depending on the severity of symptoms. West Nile fever is characterized by fever, headache and body aches, nausea and vomiting, eye pain (occasional), swollen lymph glands (occasional), and

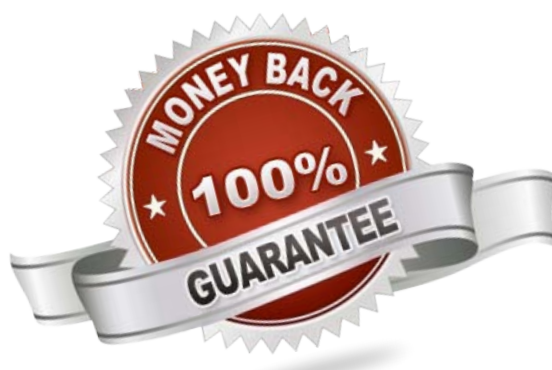
maculopapular skin rash on the chest, stomach, and back (occasional). West Nile fever affects about 20% of those who become infected, with symptoms lasting from a few days to several weeks.

For More Information – **Visit link below:**
<https://www.certsgrade.com/>

PRODUCT FEATURES

-  **100% Money Back Guarantee**
-  **90 Days Free updates**
-  **Special Discounts on Bulk Orders**
-  **Guaranteed Success**
-  **50,000 Satisfied Customers**
-  **100% Secure Shopping**
-  **Privacy Policy**
-  **Refund Policy**

16 USD Discount Coupon Code: **NB4XKTMZ**



Visit us at <https://www.certsgrade.com/pdf/ancc-fnp-bc/>